
Arrhythmias in athletes

(Ital Heart J 2004; 5 (Suppl 1): 143S-151S)

© 2004 CEPI Srl

ARRHYTHMIAS AND RELATIONSHIP TO PHYSICAL TRAINING IN ATHLETES

Alessandro Biffi, Luisa Verdile,
Antonio Pelliccia, Fredrick Fernando,
Antonio Spataro, Barry J. Maron*

*Institute of Sports Science, Department of Medicine, Italian National Olympic Committee, Rome, Italy, *Minneapolis Heart Institute Foundation, Minneapolis, MN, USA*

The athlete's heart syndrome is a composite of physiologic and structural changes that occur in response to repetitive athletic training. A growing body of literature on echocardiographic diagnosis of the athlete's heart has distinguished changes in left ventricular chamber size, wall thickness and mass from the pathologic forms of hypertrophy^{1,2}. One of the several differentiating aspects between the two forms is that the increased left ventricular cavity dimension and septal hypertrophy caused by athlete's heart typically regress in weeks to months following cessation of training. Similarly, the influence of physical training and deconditioning has been studied on sinus and atrioventricular node function (sinus bradycardia). Such adaptations are often related to changes and alterations in parasympathetic and sympathetic tone that develop in athletes as a result of training effect³. A main problem is that the differential diagnosis between non-pathologic cardiac changes associated with training and cardiac disease associated with increased risk for sudden death may be difficult in many cases. Complex ventricular arrhythmias are frequently considered a possible cause of sudden cardiac death in trained athletes and the clinical expression of an underlying cardiovascular abnormality⁴. Nevertheless, ventricular arrhythmias are a frequent finding in well-trained athletes. The impact of deconditioning on ventricular arrhythmias in athletic population has still not been studied and the aim of this study is to assess the relationship between ventricular tachyarrhythmias and physical

deconditioning in a selected population of trained athletes.

Methods

The case records of the Institute of Sports Science were reviewed from January 1984 to April 2001 and 355 athletes had been selected with 24-hour ambulatory (Holter) ECG, if they met the following criteria: > 3 premature ventricular depolarizations (PVDs) on resting 12-lead ECG (337 athletes) and/or history of palpitations (18 athletes). Based on the Holter ECG data, 71 of these 355 athletes with more frequent and complex ventricular arrhythmias (> 2,000 PVDs and > 1 burst of non-sustained ventricular tachycardia/24 hours) were selected for this study. All athletes underwent a cardiovascular evaluation including medical history and physical examination, 12-lead ECG, two-dimensional echocardiography, fatigue-limited exercise ECG, chest X-rays, and 24-hour ambulatory (Holter) ECG monitoring. Holter ECGs were recorded during periods of active training and included an average of one hour in a training session similar to that performed by the athlete, with the remaining time occupied by usual daily activities.

Based on the Italian guidelines for determining eligibility in competitive athletes with cardiovascular abnormalities⁵, which closely resemble the recommendations of the 26th Bethesda Conference⁶, each of 71 athletes was disqualified from competitive sports for a minimum of 3 months (range 12-24 weeks, mean 19 ± 5.7 weeks). After deconditioning, 50 athletes underwent again a cardiovascular evaluation, including a 24-hour Holter ECG performed as before the deconditioning. Athletes with particularly frequent and complex PVDs on ambulatory ECG monitoring were selected on a clinical basis to undergo additional testing for the purpose of detecting or defining underlying cardiovascular disease, including magnetic resonance imaging, nuclear scintigra-

phy, endomyocardial biopsy and electrophysiological study with programmed ventricular stimulation. The mean age of the athletes was 26.2 ± 10.8 years (range 18-33 years). Athletes had periodic evaluations every 6 to 12 months over the follow-up period of 2 to 15 years (mean 8.8 ± 6.0 years). At the time of the first Holter monitoring no athlete was taking antiarrhythmic or other cardioactive medications.

Data are expressed as mean \pm SD. Differences between means were assessed by using unpaired or paired Student's t-test where appropriate. A two-tailed p-value < 0.05 was considered as statistically significant.

Results

Frequency of PVDs at Holter ECG recording performed during training ranged from 2.089 to 43.151 (mean 10.850 ± 7.500), including 24 (34%) who had > 10.000 PVDs/24 hours. Each of the 71 athletes had > 1 couplets (mean 70 ± 22 , range 7-280). Thirty-eight of these 71 athletes (54%) also had 1 to 179 bursts of non-sustained ventricular tachycardia (mean 4), consisting of 3 to 28 consecutive beats, at heart rates of 130 to 270 b/min. In addition 9 of 24 athletes with > 10.000 PVDs had > 1 runs of non-sustained ventricular tachycardia. Only 8 athletes (11%) reported palpitations and none had episodes of impaired consciousness or other cardiac symptoms.

After deconditioning, 30 of 50 athletes (60%) showed a significant improvement of the arrhythmia (to < 500 PVDs and/or to < 2 couplets/24 hours). In 8 of these 30 athletes the arrhythmia disappeared completely. PVDs, couplets and non-sustained ventricular tachycardia showed a significant reduction after deconditioning.

Twenty-one of 71 athletes showed the presence of cardiovascular abnormalities: 7 athletes had arrhythmogenic right ventricular cardiomyopathy, 6 had mitral valve prolapse, 4 had dilated cardiomyopathy and 4 myocarditis. Out of 30 athletes who showed an improvement of the arrhythmia after deconditioning, 20 athletes (66%; $p = 0.02$) did not have cardiovascular abnormalities. Of these 20 without cardiovascular abnormalities, 8 athletes showed a complete disappearance of the arrhythmia after deconditioning. In the remaining 20 athletes with no improvement of the arrhythmia after detraining, there was no statistical difference between athletes with and without cardiovascular abnormalities.

Each of the 71 athletes were disqualified from competitive sports, based on the Italian guidelines for determining eligibility in competitive athletes with cardiovascular abnormalities. One of these athletes died suddenly, a 24-year-old man with arrhythmogenic right ventricular cardiomyopathy, while participating in a competitive field-hockey game (against medical advice), 6 months after official disqualification. The other 70 athletes survived to the end of follow-up period without incurring cardiac symptoms or events. No athlete has started again to practice sports at this moment.

References

1. Pelliccia A, Maron BJ, Spataro A, Proschan MA, Spirito P. The upper limit of physiologic cardiac hypertrophy in highly trained elite athletes. *N Engl J Med* 1991; 324: 295-301.
2. Maron BJ, Pelliccia A, Spirito P. Cardiac disease in young trained athletes: insights into methods for distinguishing athlete's heart from structural heart disease, with particular emphasis on hypertrophic cardiomyopathy. *Circulation* 1995; 91: 1596-1601.
3. Iellamo F, Legramante JM, Pigozzi F, et al. Conversion from vagal to sympathetic predominance with strenuous training in high-performance world class athletes. *Circulation* 2002; 105: 2719-24.
4. Biffi A, Pelliccia A, Verdile L, et al. Long-term clinical significance of frequent and complex ventricular tachyarrhythmias in trained athletes. *J Am Coll Cardiol* 2002; 40: 446-52.
5. Cardiological protocols on determining eligibility for competitive sports 2003. Organizing Cardiologic Committee on Eligibility for Sports (COCIS). Roma: CESI, 2003.
6. Maron BJ, Mitchell JE. 26th Bethesda Conference. Recommendations for determining eligibility for competition in athletes with cardiovascular abnormalities. *J Am Coll Cardiol* 1994; 24: 848-99.

VENTRICULAR ARRHYTHMIAS WITH LEFT BUNDLE BRANCH BLOCK MORPHOLOGY IN ATHLETES

Paolo Zeppilli, Massimiliano Bianco, Serena Bria, Fabrizio Colella, Vincenzo Palmieri

Sports Medicine School, Catholic University, Rome, Italy

Background

In our country, premature ventricular beats (PVBs) at rest and/or exercise electrocardiogram (ECG) are the most frequent cause for consulting a cardiologist in subjects undergoing pre-participation screening for competitive sports¹. Occurrence of ventricular arrhythmias in apparently healthy and fit athletes often gives rise to doubts and controversies among experts, especially as far as clinical significance, outcome and eligibility for sports activity are concerned.

Clinical significance of ventricular tachyarrhythmias in athletes

Up to now, there are little data available about the significance and long-term outcome of PVBs in apparently healthy athletes, especially when they are frequent and complex. Recently, Biffi et al.² have suggested that ventricular tachyarrhythmias are "common in trained athletes and are usually unassociated with underlying cardiovascular abnormalities ... do not convey adverse clinical significance, appear to be an expression of athlete's heart syndrome". This "optimistic" point of view closely follows that proposed by Kennedy³ about 20 years ago in the general population and reaffirmed by the same

author on his editorial comment to Biffi's paper⁴. More recently, Heidbuchel et al.⁵ have strongly contrasted this point of view, affirming that "complex ventricular tachyarrhythmias do not necessarily represent a benign finding in endurance athletes ... Endurance athletes with arrhythmias have a high prevalence of right ventricular structural and/or arrhythmic involvement. Endurance sports seems to be related to the development and/or progression of the underlying arrhythmogenic substrate".

Actually, both Biffi's and Heidbuchel's papers probably have selection bias and critical points^{4,6}. Most of Heidbuchel's athletes were professional cyclists, referred because of presyncope or syncope, or for symptoms during exertion. Therefore, they likely represent a selected group of "symptomatic" subjects with a high probability of having congenital or acquired arrhythmogenic substrate, namely a concealed form of arrhythmogenic right ventricular cardiomyopathy (ARVC)^{7,8} and/or myocarditis^{9,10}, which may be "triggered" by exhaustive training alone, or by additional factors, such as drug abuse¹¹.

On the contrary, the large majority of subjects (65%) in Biffi's series were asymptomatic and ventricular arrhythmias had been discovered during a routine preparticipation screening program for competitive athletes. Furthermore, in respect to Heidbuchel's series, additional investigations were performed in a minority of athletes: a nuclear magnetic resonance in 11% alone and an electrophysiological study, to explore inducibility of malignant ventricular tachyarrhythmias, in only 6.7% of cases, namely those with the most complex and frequent arrhythmias at Holter monitoring. As a consequence of this, beyond the small percentage (7%) of athletes having overt cardiac abnormalities, such as mitral valve prolapse, or organic heart disease, many others might have a concealed arrhythmogenic substrate such as a myocarditis⁹, false tendons¹², dimensional and/or motion abnormalities in the right ventricular outflow tract^{13,14}, focal abnormalities in the Purkinje system acting as a trigger of frequent and complex PVBs and idiopathic ventricular fibrillation¹⁵.

In our opinion, the truth stands in the middle. In our long-term experience, when noninvasive and invasive investigations are applied extensively to athletes with PVBs and/or ventricular tachyarrhythmias, the majority of them show subtle cardiac abnormalities or overt heart diseases.

Significance and outcome of premature ventricular beats with left bundle branch block morphology

The most common form of PVBs encountered both in normal and athletic population is that showing a left bundle branch block (LBBB) morphology, indicating their origin from the right ventricle^{1,2,16,17}. In particular, the most frequent form is that with an inferior axis on frontal plane, which arises from right ventricular outflow tract. In 1969 Rosenbaum¹⁶ defined this kind of PVB as benign, "typical of normal subjects", and some authors suggested that it may be part of cardiovascular changes due to regular physical training, known as athlete's heart syndrome¹⁷⁻¹⁹.

Unfortunately, most of the symptomatic athletes with right ventricular pathological findings described by Heidbuchel and subjects with concealed or overt ARVC who died suddenly during exercise, also have LBBB-PVBs with both vertical, leftward or superior axis on frontal plane^{7,8,20,21}.

To offer a contribution to the discussion, we reanalyzed a population of 123 sportsmen referred for LBBB-PVBs. All had complete ECG and Holter documentation of arrhythmias and a thorough echocardiographic examination, with particular attention on the right ventricle. In addition, 73 out of the 123 athletes (59%) had a routine cardiac magnetic resonance and 8 underwent invasive investigation, including endomyocardial biopsy. Our analysis confirms that middle-term prognosis in these subjects is good, regardless of the number and complexity of arrhythmias and of the presence or absence of underlying heart diseases. However:

- only one third (41/123 sportsmen) had an "apparently normal" heart;
- one third (42/123) had "minor" right ventricular abnormalities, i.e. mild global or segmental dilation of the right ventricle, focal sacculations, trabecular and/or moderator band anomalies, at echocardiogram and/or magnetic resonance. Three of them had sustained right ventricular outflow tract tachycardia (1 underwent a successful radiofrequency ablation) and 6 had an associated mitral valve prolapse;
- one third (40/123) showed structural heart diseases, most commonly ARVC (19 cases), active or healed myocarditis (17 cases), dilated cardiomyopathy (3 cases) and anomalous origin of coronary artery (1 case).

So, in the presence of LBBB-PVBs, sports physicians and cardiologists could face three different situations:

1. the athlete shows an "apparently normal" heart at the end of complete and accurate investigations;
2. the athlete exhibits non-specific right ventricular anomalies at echocardiography and/or magnetic resonance. In this case, the physician has to decide if PVBs are an early manifestation of ARVC, which is a progressive disease^{22,23}, or a localized, focal, abnormality of the right ventricle with minimal or no probability of getting worse in the time and a fairly benign prognosis^{13,14}. The presence of an otherwise normal ECG at rest, as well as overdrive suppression of PVBs during exercise, seems to support the latter hypothesis. In a recent survey by Gaita et al.¹⁴ in 61 patients with LBBB-PVBs, none died suddenly during a mean follow-up of 15 years. Furthermore, 50% of them showed disappearance of PVBs at Holter monitoring¹⁴, a finding not uncommon also in our experience in athletes. This aspect gets more importance considering the growing experience and safety of radiofrequency ablation procedures in the successful treatment of such arrhythmias²⁴⁻²⁶. Recently, it has been suggested that electrophysiological study may help to differentiate arrhythmias due to an overt ARVC from idiopathic, benign, ventricular arrhythmias which may benefit from catheter ablation²⁷;
3. LBBB-PVBs are the expression of pathological conditions, most frequently ARVC and myocarditis with prevalent right ventricular involvement, and suggests the opportunity of discontinuing competitive sport⁹.

In addition, sports physicians and cardiologists should be aware that LBBB-PVBs may be, although more rarely, associated with a left ventricular disease such as hypertrophic and dilated cardiomyopathy, anomalous origin of coronary arteries and/or a bicuspid aortic valve (Bria et al., unpublished data). However, in this case, the origin from the left septum or from areas close to aortic sinuses of PVBs can be argued by the presence of a non-typical LBBB morphology, characterized by a tall and broad R wave in V₁ lead and an early transition of QRS in precordial leads²⁸⁻³¹.

Conclusion

LBBB-PVBs in the athletic population have usually a good middle and long-term prognosis, even if in a consistent number of cases an organic heart disease or "minor" cardiac abnormalities, mostly in the right ventricle, are appreciable after a thorough cardiac examination, including an accurate echocardiographic study, with particular attention on the right ventricle and magnetic resonance imaging.

Even if the right ventricle is usually involved in the genesis of LBBB-PVBs, sometimes arrhythmias may arise from the left ventricle, mostly from foci localized in the left side of septum or close to the aortic cusps, both in the absence or presence of pathological conditions affecting the left ventricle. In this case, a correct analysis of resting ECG can help the sports physician and cardiologist to identify a left side origin of LBBB-PVBs and to orient the prognosis and the eligibility of athlete for sport.

References

- Santini C, Palmieri V, Vannicelli R, Cameli S, Zeppilli P. L'esperienza dei centri di III livello. Il Centro di Medicina dello Sport del Policlinico A. Gemelli, Roma. In: Cupelli S, ed. Proceedings of 6th National Congress of the Italian Society of Sports Cardiology. Orioli (FI), 2000: 103.
- Biffi A, Pelliccia A, Verdile L, et al. Long-term clinical significance of frequent and complex ventricular tachyarrhythmias in trained athletes. *J Am Coll Cardiol* 2002; 40: 446-52.
- Kennedy HL, Whitlock JA, Sprague MK, Kennedy LJ, Buckingham TA, Goldberg RJ. Long-term follow-up of asymptomatic healthy subjects with frequent and complex ventricular ectopy. *N Engl J Med* 1985; 312: 193-7.
- Kennedy H. Editorial comment. Ventricular ectopy in athletes. Don't worry ... more good news. *J Am Coll Cardiol* 2002; 40: 453-6.
- Heidbuchel H, Hoogsteen J, Fagard R, et al. High prevalence of right ventricular involvement in endurance athletes with ventricular arrhythmias. Role of an electrophysiologic study in risk stratification. *Eur Heart J* 2003; 24: 1473-80.
- Mont L, Brugada J. Endurance athletes: exploring the limits and beyond. *Eur Heart J* 2003; 24: 1469-70.
- Furlanello F, Bertoldi A, Dallago M, et al. Cardiac arrest and sudden death in competitive athletes with arrhythmogenic right ventricular dysplasia. *Pacing Clin Electrophysiol* 1998; 21: 331-5.
- Corrado D, Basso C, Thiene G. Sudden cardiac death in young people with apparently normal heart. *Cardiovasc Res* 2001; 50: 399-408.
- Zeppilli P, Santini C, Palmieri V, Vannicelli R, Giordano A, Frustaci A. Role of myocarditis in athletes with minor arrhythmias and/or echocardiographic abnormalities. *Chest* 1994; 106: 373-80.
- Frustaci A, Cameli S, Zeppilli P. Biopsy evidence of atrial myocarditis in an athlete developing transient sinoatrial disease. *Chest* 1995; 108: 1460-2.
- Zeppilli P, Caretta F. Doping ed apparato cardiocircolatorio. In: Zeppilli P, ed. *Cardiologia dello Sport*. Roma: CESI, 2001: 991-1036.
- Suwa M, Hirota Y, Nagao H, Kino M, Kawamura K. Incidence of the coexistence of left ventricular false tendons and premature contractions in apparently healthy subjects. *Circulation* 1984; 70: 793-8.
- Proclemer A, Basadonna PT, Slavich GA, Miani D, Fresco C, Fioretti PM. Cardiac magnetic resonance imaging findings in patients with right ventricular outflow tract premature contractions. *Eur Heart J* 1997; 18: 2002-10.
- Gaita F, Giustetto C, Di Donna P, et al. Long-term follow-up of right ventricular monomorphic extrasystoles. *J Am Coll Cardiol* 2001; 38: 364-70.
- Haissaguerre M, Shoda M, Jais P, et al. Mapping and ablation of idiopathic ventricular fibrillation. *Circulation* 2002; 106: 962-7.
- Rosenbaum MB. Classification of ventricular extrasystoles according to form. *J Electrocardiol* 1969; 2: 289-98.
- Pagliaricci C, Boni G, Caretta F, et al. Variabilità delle aritmie in giovani sportivi sani in Holter periodici effettuati per ricerca scientifica. In: Guiducci U, ed. *Cardiologia e sport*. Proceedings of the 11th National Congress of the Italian Society of Sports Cardiology. Pavia: EDIMES, 1999: 204.
- Huston P, Puffer JC, MacMillan RW. The athletic heart syndrome. *N Engl J Med* 1985; 315: 24-32.
- Bjornstad H, Smith H, Storstein L, Meen HD, Hals O. Electrocardiographic and echocardiographic findings in top athletes, athletic students and sedentary controls. *Cardiology* 1993; 82: 66-74.
- Thiene G, Nava A, Corrado D, et al. Right ventricular cardiomyopathy and sudden death in young people. *J Am Coll Cardiol* 1988; 318: 129-33.
- Corrado D, Basso C, Thiene G, et al. Spectrum of clinicopathologic manifestation of arrhythmogenic right ventricular cardiomyopathy/dysplasia: a multicenter study. *J Am Coll Cardiol* 1997; 30: 1512-20.
- Corrado D, Basso C, Thiene G. Arrhythmogenic right ventricular cardiomyopathy: diagnosis, prognosis and treatment. *Heart* 2000; 83: 588-95.
- Gemayel C, Pelliccia A, Thompson PD. Arrhythmogenic right ventricular cardiomyopathy. *J Am Coll Cardiol* 2001; 38: 1773-881.
- Kamakura S, Shimizu W, Matsuo K, et al. Localization of optimal ablation site of idiopathic ventricular tachycardia from right and left ventricular outflow tract by body surface ECG. *Circulation* 1998; 98: 1525-33.
- Seidl K, Schumacher B, Hauer B, et al. Radiofrequency catheter ablation of frequent monomorphic ventricular ectopic activity. *J Cardiovasc Electrophysiol* 1999; 10: 924-34.
- Krittayaphong R, Sriratanasathavorn C, Bhuripanyo K, et al. One-year outcome after radiofrequency catheter ablation of symptomatic ventricular arrhythmia from right ventricular outflow tract. *Am J Cardiol* 2002; 89: 1269-74.
- Niroomand F, Carbucicchio C, Tondo C, et al. Electrophysiological characteristics and outcome in patients with idiopathic right ventricular arrhythmia compared with arrhythmogenic right ventricular dysplasia. *Heart* 2000; 87: 41-7.
- Callans DJ, Menz V, Schwartzman D, et al. Repetitive monomorphic tachycardia from the left ventricular outflow tract: electrocardiographic patterns consistent with a left ventricular site of origin. *J Am Coll Cardiol* 1997; 29: 1023-7.
- Callans DJ. Idiopathic ventricular tachycardia: is radiofrequency ablation the first line of therapy? In: Raviele A, ed.

- Proceedings of Cardiac Arrhythmias 2003. 8th International Workshop on Cardiac Arrhythmias. Venice, 2003: 348-55.
30. Kanagaratnum L, Tomassoni G, Scweiker R, et al. Ventricular tachycardia arising from the aortic sinus of Valsalva: an under-recognized variant of left ventricular outflow tract tachycardia. *J Am Coll Cardiol* 2001; 37: 1408-14.
31. Marchlinski FE, Lin D, Dixit S, et al. Ventricular tachycardia from the aortic cusps: localization and ablation. In: Raviele A, ed. Proceedings of Cardiac Arrhythmias 2003. 8th International Workshop on Cardiac Arrhythmias. Venice, 2003: 357-70.

ADVANCED SPORTS ACTIVITY RESUMPTION AFTER PERCUTANEOUS TRANSLUMINAL CORONARY ANGIOPLASTY REVASCLARIZATION

Nicola Muià, Massimo Pantaleoni, Luca Piccinini, Umberto Guiducci

Department of Cardiology, S. Maria Nuova Hospital, Reggio Emilia, Italy

Regular exercise is currently recommended for patients with ischemic heart disease. It produces clinical benefits such as improved exercise tolerance and quality of life, decreased mortality and lower costs due to lower rehospitalization rates. Furthermore regular exercise may be effective in improving work capacity even in patients with moderate-to-severe ventricular dysfunction¹. There are certain differences between normal subjects and athletes regarding the physiologic mechanisms which lead to positive effects on the cardiovascular system. The effects of physical training and in particular the aerobic type can be divided into central and peripheral effects. In the healthy subject the mean central effects on the heart are: sympathetic tone reduction, myocardial mass and left ventricular end-diastolic volume increase.

There are reports in the literature that have shown similar changes in the autonomous nervous system in patients with ischemic heart disease². Furthermore morphologic cardiac adaptation to physical training has been seen in several studies³. Patients with heart disease perform a modest amount of physical training and have an increased number of collateral coronary vessels. We can classify a patient with known ischemic heart disease if he/she has:

- positive history of myocardial infarction (confirmed by clinical, electrocardiographic and cardiac enzyme criteria);
- positive history of angina pectoris (confirmed by symptomatic ST modification on the standard ECG, during Holter monitoring or by a positive stress test);
- prior myocardial revascularization (coronary artery bypass grafting or percutaneous transluminal coronary angioplasty-PTCA).

For these patients the most important prognostic factors are: the degree of left ventricular function, coronary artery disease extension, inducible ischemia and electrical instability (complex ventricular arrhythmias). For this reason it is necessary to evaluate global left ventricular function at rest by echocardiography, perform limited for symptoms stress test in pharmacological

washout and Holter monitoring. Based on the results of these tests these subjects can be divided into two groups: 1) low risk (ejection fraction > 50%; normal exercise tolerance according to age; absence of inducible ischemia; absence of complex ventricular arrhythmias at rest and/or during exercise; absence of critical/subcritical coronary stenosis > 50%); 2) elevated risk (ejection fraction < 50%; exercise-induced myocardial ischemia; complex ventricular arrhythmias at rest and/or during exercise; significant coronary stenosis > 50% in at least one coronary vessel).

The possibility for a patient with ischemic heart disease of practising sports depends on two factors: 1) his/her cardiocirculatory condition and 2) type of sports activity. It is also important to underline that the type of sports activity must be recreational and/or therapeutic and never agonistic. Not all patients with ischemic heart disease can be enrolled in an exercise training program or a competitive sporting event. The following patients can be considered candidates for sports activity:

- ischemic heart disease patients with stable secondary angina (medium to elevated threshold level; 9/10 METS);
- patients who underwent PTCA without residual ischemic signs or symptoms;
- patients with prior myocardial infarction, asymptomatic without left ventricular dysfunction, complex ventricular arrhythmias or signs of residual ischemia;
- patients who underwent coronary artery bypass grafting without residual ischemia or left ventricular dysfunction.

Furthermore it is important to consider perfusion pressure and peripheral vascular resistance because reduced left ventricular contractile capacity and residual coronary stenosis may limit cardiac capacity to adapt to increase levels of work.

PTCA was introduced in clinical practice in the late 70's as a non-surgical method for coronary arterial revascularization. Early reports demonstrated that PTCA could reduce the severity of coronary stenosis and decrease or eliminate objective and subjective manifestations of ischemia⁴. With experience and time this technique became progressively more refined and largely used. Observational reports of large numbers of patients confirmed that coronary angioplasty could be applied to broad groups of coronary patients with higher rates of success and lower rates of complications when compared to initial experiences⁵. Randomized clinical trials have assessed the outcomes of patients treated by a strategy of initial angioplasty to one of medical therapy alone or to coronary artery bypass surgery. The results of these trials have clarified the utility of angioplasty in terms of effectiveness, complications and patient selection⁶.

According to the most recent protocols of the Cardiologic Organizing Committee for Sports Eligibility (COCIS 2003), patients with single coronary stenosis and favorable PTCA can consider practicing medium to elevated sports activity at least 1 year after the procedure with clinical follow-up every 6 months⁷.

Our sports activity center for middle to advanced aged subjects and functionally integrated with the Department of Cardiology, evaluates nearly 2500 sub-

jects per year; all older than 35 years; from 2001 we selected patients with single vessel coronary artery disease efficiently treated with coronary angioplasty; they were all athletes who expressed the desire to practice sports activity at a level superior than one may consider recreational. One may consider a global risk evaluation of the patient which includes not only the low risk criteria expressed by the COCIS but even PCR and homocysteinemia normalization, the absence of comorbidity metabolic disorders and cigarette smoking.

Our study population consisted of 20 male subjects, mean age 63 ± 9.5 years who met the preceding criteria and therefore entered our registry 6 months after coronary angioplasty.

The patients performed the following activities: 9 were cyclists, 7 marathon runners, 2 skiers, 1 arch thrower and 1 alpine skier. All patients were enrolled in an individualized evaluation protocol that consisted of: integrated cardiorespiratory evaluation in order to define personal physical capacity; after which a maximal stress test and Holter monitoring reevaluation was performed every 3 months. Two patients were excluded (1 jogger and 1 cyclist) for the presence of strummental abnormalities (silent ischemia during exercise, 11 months after coronary angioplasty and non-complex ventricular extrasystole, 9 months after PTCA).

The remaining 18 subjects continued their specific physical training without showing adverse events during a mean follow-up period of 2.8 years. After the publication of the COCIS 2003 protocols 6 patients asked and obtained physical and agonistic eligibility to participate in sporting events; none had adverse events.

One patient returned to his previously activity of ski instructor participating in a competitive skiing event.

When one speaks of ischemic heart disease and its various forms, it is clear that not all patients possess the requirements to start, in a safe way, a physical activity program or a competitive sports event. It is therefore important that the cardiologist is familiar with the physiological characteristics of different sports subspecialties and the pathophysiological mechanisms that limit physical activity in patients with ischemic heart disease.

The data of our patients who underwent constant and repetitive follow-ups are compatible with resuming these activities in patients with a low risk profile and followed by an equipe which is specifically trained to deal with these types of problems.

References

1. Giannuzzi P, Tavazzi L, Tamporelli PL, et al. Long term physical training and left ventricular remodeling after anterior myocardial infarction: results of exercise in anterior myocardial infarction (EAMI) trial. *J Am Coll Cardiol* 1993; 22: 1821-9.
2. Cooksey JD, Reilly P, Brown S, et al. Exercise training and plasma catecholamines in patients with ischemic heart disease. *Am J Cardiol* 1978; 42: 372-6.
3. Guiducci U, Pantaleoni M, Manari A, et al. L'attività sportiva nella prevenzione e riabilitazione della cardiopatia ischemica. In: Zeppilli P, ed. *Cardiologia dello Sport*. Roma: CESI, 2001.
4. Miller DD, Verani MS. Current status of myocardial perfusion imaging after percutaneous transluminal coronary angioplasty. *J Am Coll Cardiol* 1994; 24: 260-6.

5. O'Keefe JH Jr, Rutherford BD, McConahay DR, et al. Multivessel coronary angioplasty from 1980 to 1989: procedural results and long-term outcome. *J Am Coll Cardiol* 1990; 16: 1097-102.
6. Coronary angioplasty versus coronary artery bypass surgery: the Randomised Intervention Treatment of Angina (RITA) trial. *Lancet* 1993; 341: 573-80.
7. Autori vari. COCIS (Comitato Organizzativo Cardiologico per l'Idoneità allo Sport). *Protocolli cardiologici per il giudizio di idoneità allo sport agonistico*. Roma: CESI, 2003.

PROGRESS IN NON-INVASIVE INVESTIGATIONS IN ATHLETES WITH ARRHYTHMIA-RELATED T-WAVE ALTERNANS

Giorgio Galanti, Paolo Manetti, Francesco Furlanello*

*Sports Medicine Center, University of Florence, Florence,
*Department of Clinical Arrhythmia and Electrophysiology,
Istituto Policlinico San Donato, San Donato Milanese (MI), Italy*

Background. Several studies confirmed the equivalence of microvolt T-wave alternans (mTWA) with electrophysiology test in heart disease patients, but no data are available in sportive population with ectopic ventricular arrhythmias, where it is important to separate a parapsychologic arrhythmic subset from a pathological one.

Methods. We prospectively studied 52 trained competitive athletes, including elite types (mean age 28.2 ± 11.5 years), symptomatic in 85% of cases for prolonged palpitations and syncope, without any overt structural heart disease at standardized screening. All athletes underwent the mTWA exercise stress test, using the heart wave system with micro-V sensors (Cambridge Heart Inc., Boston, MA, USA) and then an electrophysiological study (EPS) to evaluate inducibility to sustained ventricular tachycardia during programmed electrical stimulation.

Results. The mTWA test was positive in 7 symptomatic subjects (15%), indeterminate in 3 (7%), and negative for the remaining 76%; 41/42 negative mTWA subjects were also negative at the EPS, without any syncope or sustained ventricular tachycardia during 25.3 months of follow-up. In the positive mTWA-test subjects, 5 (72%) were positive for inducibility of rapid sustained monomorphic ventricular tachycardia in EPS, one was positive for severe sustained atrial tachyarrhythmias, one refused EPS. We were able to pronounce a correct diagnosis of lymphocytic myocarditis for only one mTWA and EPS-positive subject. For the other 4 positive patients with arrhythmogenic micropathology, severe arrhythmic events were revealed in the follow-up and aggressive hybrid treatment was necessary.

Conclusions. mTWA study seems to be a useful, non-invasive tool for evaluating arrhythmic risk in the athletic population. The mTWA test showed a high negative predictive value, using both EPS and the follow-up observation for severe arrhythmic cardiac events as an endpoint. The positive predictive value was present in a limited number of cases who were however all subjects with a high risk of sudden arrhythmic death.

WHAT CAN WE GET USING MAGNETIC RESONANCE IMAGING, ANGIOGRAPHY AND SPECTROSCOPY?

Francesco Sardanelli, Matteo Quarenghi

Diagnostic Imaging, Istituto Policlinico San Donato, San Donato Milanese (MI), Italy

Cardiac magnetic resonance (MR) imaging can give important information in several diseases associated with ventricular arrhythmias in athletes: hypertrophic cardiomyopathy, right ventricular (RV) dysplasia, idiopathic dilated cardiomyopathy, coronary artery anomalies, and coronary artery disease. In hypertrophic cardiomyopathy, MR enables us to define the disease extent and gives accurate information about myocardial thickness and thickening, mitral regurgitation and dynamic obstruction in the left ventricular outflow tract. In subjects with RV arrhythmia with left bundle branch block morphology, MR imaging should be considered a mandatory diagnostic step for its ability to show otherwise undetected areas of adipose replacement triggering RV ectopies and to detect RV trabecular disarray, bulges and aneurysms, allowing the diagnosis of RV dysplasia. However, not all patients with signal suggesting myocardial adipose replacement can be considered as affected by the disease: there is a grading of MR findings in relation to the severity of the RV arrhythmia. In patients with initial dilated cardiomyopathy due to myocarditis, MR can detect myocardial inflammation and edema, monitoring the effect of therapy. MR imaging is a useful tool in evaluating myocardial hypertrophy and function of the athlete's heart and also a valuable non-invasive method to visualize their coronary arteries. Finally, cardiac ³¹P MR spectroscopy is devoted to investigate myocardial metabolism, based on the in vivo evaluation of high-energy phosphates.

Introduction

Sudden cardiac death is uncommon in athletes under the age of 30 years, more frequent in older athletes, frequently due to ventricular arrhythmias in unknown heart disease¹. Cardiac magnetic resonance (MR) can give important information in several cardiac diseases associated with ventricular arrhythmias in athletes: hypertrophic cardiomyopathy, right ventricular (RV) dysplasia, idiopathic dilated cardiomyopathy, coronary artery anomalies, and coronary artery disease. The aim of this paper is to describe the diagnostic contribution of MR morphologic and functional imaging, coronary angiography and localized spectroscopy in diagnosing and managing these diseases.

Cardiac magnetic resonance imaging in athletes' arrhythmias

In patients with hypertrophic cardiomyopathy, MR enables us to define the disease extent more precisely than transthoracic echocardiography, changing the disease distribution (apical, symmetric, asymmetric) in a non-negligible fraction of cases. Functional cine-MR gives accurate information about myocardial thickness and thick-

ening, as well as about mitral regurgitation and dynamic obstruction in the left ventricular outflow tract².

In subjects with RV arrhythmia with left bundle branch block morphology MR imaging should be considered a mandatory diagnostic step for its ability to show otherwise undetected myocardial structural abnormalities. Using a short time of echo (TE), signal hyperintensities can be clearly demonstrated within RV (and sometimes left ventricular) walls (Fig. 1), suggesting areas of adipose replacement triggering RV ectopies. MR imaging enables us to detect also RV trabecular disarray, bulges and aneurysms³.

However, we must take into account that not all patients with signal RV myocardial adipose replacement can be considered as affected by RV disease. We reviewed 124 patients with RV arrhythmia with left bundle branch block morphology and 38 healthy volunteers as controls. The RV arrhythmias were divided into three groups: 45 patients with episodes of RV sustained tachycardia and of polymorphic premature beats (group A); 36 patients with RV outflow tract sustained or not sustained tachycardia (group B); 43 patients with RV monomorphic premature beats (group C). The percentage of patients with adipose replacement decreased from 91 (group A) to 72% (group B), to 67% (group C); that of patients with RV bulges from 75 to 39%, to 14%, respectively. RV aneurysms were found only in 33% of group A. Interestingly, also in 11% of the controls (4 subjects) foci of adipose replacement were found with MR; the 24-hour Holter ECG monitoring showed repetitive RV monomorphic premature beats. Thus, there is a grading of MR findings in relation to the severity of the RV arrhythmia⁴.

A sure diagnosis of RV dysplasia is difficult especially in the early stage of its development. In 1994 McKenna defined a list of major and minor criteria including family history, ECG and transthoracic echocardiography, angiographic, MR, and pathologic findings for diagnosing RV dysplasia^{5,6}. In the last decade MR imaging gained an increasing role in discovering myocardial structural changes in these patients, avoiding unnecessary cardiac catheterization and myocardial biopsy. However the detection of only small adipose replacement in the RV wall cannot be misdiagnosed for RV dysplasia also in subjects with abnormal ECG with left bundle branch block morphology.

In patients with initial dilated cardiomyopathy due to myocarditis, MR can detect myocardial inflammation and edema as hyperintensity on long TE images⁷ and as contrast enhancement after intravenous injection of paramagnetic contrast agent⁸. The effect of therapy can be easily demonstrated evaluating the reduction or resolution of these signal hyperintensities and abnormal contrast uptake.

Cine-magnetic resonance and magnetic resonance coronary angiography in athletes

Physiological reactions of the cardiovascular system to long-term athletic training result in an increase of

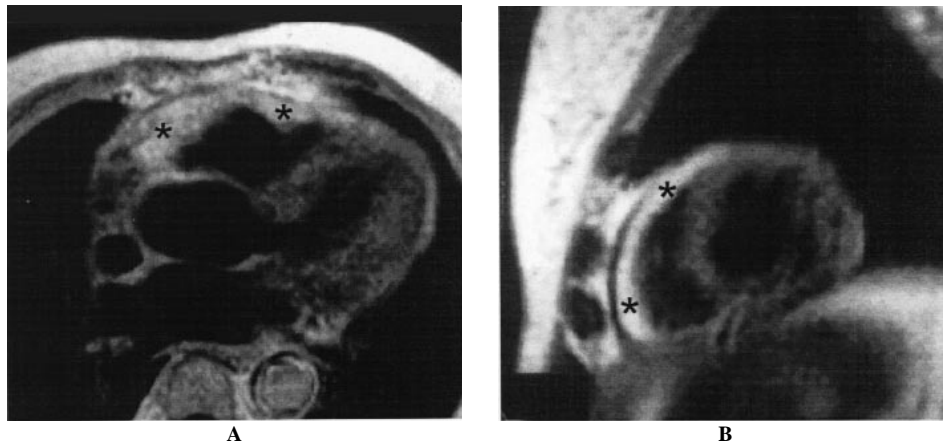


Figure 1. Right ventricular dysplasia. Long-axis (A) and short-axis (B) spin-echo sequence. Diffuse hyperintensity of the right ventricular lateral wall.

myocardial mass and ventricular volumes and function in order to sustain a continued muscular work by increasing oxygen transportation. MR imaging is a useful tool to evaluate myocardial hypertrophy and function of the athlete's heart and also a valuable non-invasive method to visualize coronary arteries.

We recently studied a group of endurance athletes (12 trained rowers) and an age-matched control group of sedentary healthy subjects with cine-MR (ECG-gated breath-hold gradient-echo sequences) and three-dimensional fat-saturated ECG- and respiratory-triggered navigator echo sequence in order to evaluate left ventricular myocardial mass and function as well as ostial coronary artery cross-sectional area. Myocardial mass was found significantly larger in athlete group than in control group, the same being for end-diastolic volume, stroke volume, left main trunk and left anterior descending coronary artery cross-sectional area. Significant correlation with myocardial mass was found for left main trunk and left anterior descending, not for circumflex and right coronary artery⁹.

More importantly, cardiac navigator echo MR angiography^{10,11} can be used to detect anomalous course of coronary arteries allowing this diagnosis in a non-invasive way and avoiding unnecessary cardiac catheterism in subject without coronary artery anomalies. The use of this approach for detecting significant stenoses due to atherosclerotic coronary artery disease is under investigation with interesting results¹².

The future: myocardial magnetic resonance spectroscopy

MR spectroscopy is a technique with a long history before and after the introduction of MR imaging in clinical practice. This technique enables us to obtain a spectral analysis of biologic materials distinguishing different molecular species due to the "chemical shift" determined by the electronic shielding of the nucleus in different molecules, giving peaks of different metabolites at different frequencies of resonance, usually reported as part per millions (ppm) independently of the mag-

netic field strength¹³. During the 80's of the past century MR spectroscopy was proposed as a new tool aimed at biochemical analysis of a volume of interest defined on the MR images - the so-called "localized MR spectroscopy"¹⁴⁻¹⁶. However, the advantage of a precise spatial localization is paid with trade-off in terms of spectral resolution, due to the relatively low field strength, usually 1.5 T. From this viewpoint, the recent introduction of clinical MR units operating from 3-4 T¹⁷ up to ultra-high fields such as 8 T¹⁸ is an open perspective of great interest.

Cardiac MR spectroscopy is mainly devoted to investigate ³¹P, due to the possibility of obtaining information on myocardial metabolism, based on the *in vivo* evaluation of high energy phosphates^{19,20}. A dedicated surface coil, placed in contact with the chest wall with the patient in prone position, is generally used.

For historical reasons, on the spectrum the most negative values are on the right, the most negative on the left of the spectrum. From right to left there will be: α - β - and γ -ATP; phosphocreatine (PCr) (assumed as conventional reference value at 0.0 ppm); phosphodiester (PDE), in particular phospholipids; inorganic phosphate (iP) and phosphomonoesters (PME), partially superimposed (Figs. 2 and 3).

Because of the known relationships between PCr, Cr, ADP, ATP and iP in energy metabolism, spectroscopy can supply relevant information on the myocardial status; ADP concentration can be inferred from its directly proportional relationship with iP/PCr ratio.

The iP/PCr ratio has been mostly used, considered as representative of the energy potential tissue volume. Of the three ATP peaks, β -ATP, not contaminated by signal from ADP, NAD⁺ and NADH, is preferred. The PCr/iP ratio is impaired by the partial overlapping between iP and PME (in particular, 2,3-diphosphoglycerate with ³¹P in position 2 coming from the blood in heart chambers). Spectral contaminations from blood signal (correctable), skeletal muscle of chest wall and diaphragm (not always correctable) and liver, can modify the PCr/ATP and should be considered. As a consequence wide variability in PCr/ATP values, ranging between 0.9 and 2.1^{20,21}.

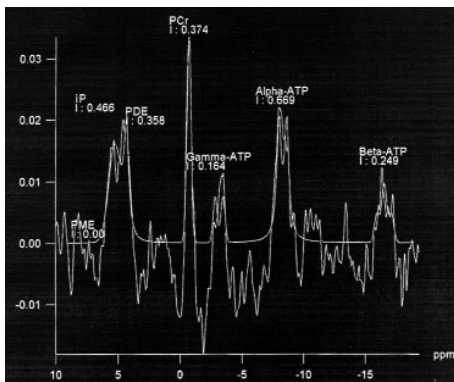


Figure 2. Myocardial ^{31}P magnetic resonance spectroscopy at 1.5 T (normal subject, chemical shift imaging technique without proton decoupling). From right to left: β -ATP (-16.3 ppm), α -ATP (-7.8 ppm) and γ -ATP (-2.7 ppm); phosphocreatine (PCr; 0.0 ppm); phosphodiester (PDE, 2.0-3.0 ppm); inorganic phosphate (iP, 3.7-5.2) and partially superimposed phosphomonoesters (PME, 5.4 and 6.3 ppm). Most significant PME component is 2,3-diphosphoglycerate of blood present in cardiac chambers.




Figure 3. Localizer image for magnetic resonance spectroscopy chemical shift imaging sequence.

However, iP and PME can be decoupled with proton decoupling. The cell pH can be measured based on the chemical shift (distance in ppm) between iP peak (pH-dependent) and that of PCr (pH-independent): 5 ppm correspond to about 0.5 unit on the pH scale (not strictly linear relationship)²².

Thus, a great potential of biochemical information could be obtained using ^{31}P MR spectroscopy in the athletes' heart. Notwithstanding, until today no study was published on this intriguing topic, neither on healthy athletes nor on athletes with arrhythmias. A future for research in this area should be warranted.

References

1. Maron BJ, Shirani J, Poliac LC, et al. Sudden death in young competitive athletes: clinical, demographic, and pathologic profiles. *JAMA* 1996; 276: 199-204.
2. Sardanelli F, Molinari G, Petillo A, et al. MRI in hypertrophic cardiomyopathy: a morphofunctional study. *J Comput Assist Tomogr* 1993; 17: 862-72.
3. Molinari G, Sardanelli F, Gaita F, et al. Right ventricular dysplasia as a generalized cardiomyopathy? Findings on magnetic resonance imaging. *Eur Heart J* 1995; 16: 1619-24.
4. Molinari G, Sardanelli F, Zandrino F, et al. Adipose replacement and wall motion abnormalities in right ventricular arrhythmias: evaluation by MR imaging. Retrospective evaluation on 124 patients. *Int J Card Imaging* 2000; 16: 105-15.
5. McKenna WJ, Thiene G, Nava A, et al. Diagnosis of arrhythmogenic right ventricular dysplasia/cardiomyopathy. Task Force of the Working Group Myocardial and Pericardial Disease of the European Society of Cardiology and of the Scientific Council on Cardiomyopathies of the International Society and Federation of Cardiology. *Br Heart J* 1994; 71: 215-8.
6. Naccarella F, Naccarelli G, Fattori R, et al. Arrhythmogenic right ventricular dysplasia: cardiomyopathy current opinions on diagnostic and therapeutic aspects. *Curr Opin Cardiol* 2001; 16: 8-16.
7. Sardanelli F, Parodi RC, Molinari G, et al. Idiopathic cardiomyopathies: evaluation by MR imaging. *Medical Imaging International* 1996; 6: 7-10.
8. McCrohon JA, Moon JC, Prasad SK, et al. Differentiation of heart failure related to dilated cardiomyopathy and coronary artery disease using gadolinium-enhanced cardiovascular magnetic resonance. *Circulation* 2003; 108: 54-9.
9. Zandrino F, Molinari G, Smeraldi A, et al. Magnetic resonance imaging of athlete's heart: myocardial mass, left ventricular function, and cross-sectional area of the coronary arteries. *Eur Radiol* 2000; 10: 319-25.
10. Plein S, Ridgway JP, Jones TR, Bloomer TN, Sivananthan MU. Coronary artery disease: assessment with a comprehensive MR imaging protocol. *Radiology* 2002; 225: 300-7.
11. Taylor AM, Keegan J, Jhooti P, Firmin DN, Pennell DJ. Calculation of a subject-specific adaptive motion-correction factor for improved real-time navigator echo-gated magnetic resonance coronary angiography. *J Cardiovasc Magn Reson* 1999; 1: 131-8.
12. Sardanelli F, Molinari G, Zandrino F, Balbi M. 3D navigator echo magnetic resonance coronary angiography in detecting stenoses of the major epicardial vessels using contrast coronary angiography as a standard of reference. *Radiology* 2000; 214: 808-14.
13. Salibi N, Brown MA. *Clinical MR spectroscopy. First principles.* New York, NY: Wiley-Liss, 1998.
14. Bottomley PA. Human in vivo NMR spectroscopy in diagnostic medicine: clinical tool or research probe? *Radiology* 1989; 170: 1-15.
15. Aisen AM, Chenevert TL. MR spectroscopy: clinical perspective. *Radiology* 1989; 173: 593-9.
16. Daly PF, Cohen JS. Magnetic resonance spectroscopy of tumors and potential in vivo clinical applications: a review. *Cancer Res* 1989; 49: 770-9.
17. Takahashi M, Uematsu H, Hatabu H. MR imaging at high magnetic fields. *Eur J Radiol* 2003; 46: 45-52.
18. Robitaille PM, Warner R, Jagadeesh J, et al. Design and assembly of an 8 Tesla whole-body MR scanner. *J Comput Assist Tomogr* 1999; 23: 808-20.
19. Bottomley PA, Weiss RG, Hardy CJ, Baumgartner WA. Myocardial high-energy phosphate metabolism and allograft rejection in patients with heart transplants. *Radiology* 1991; 181: 67-75.
20. Shaefer S. Valutazione del metabolismo miocardico mediante risonanza magnetica spettroscopica. In: Brundage BH, ed. *Tecniche di imaging in cardiologia clinica.* Salerno: Momento Medico, 1993: 389-99.
21. Beyerbach HP, Vliegen HW, Lamb HJ, et al. Phosphorus magnetic resonance spectroscopy of the human heart: current status and clinical implications. *Eur Heart J* 1996; 17: 1158-66.
22. Elster AD. *Questions and answers in MRI.* St Louis, MO: Mosby, 1994: 217-23.